

Oncological outcomes of 356 patients undergoing focal ablative salvage therapy (HIFU or cryotherapy) following radiation failure for prostate cancer

Deepika Reddy, Taimur T. Shah, Marieke van Son, Stephanie Guillaumier, Feargus Hosking-Jervis, Tim Dudderidge, Stuart McCracken, Raj Nigam, Richard Hindley, Neil McCartan, Naveed Afzal, Henry Lewi, Raj Persad, Jaspal Viridi, Clement Orczyk, Caroline Moore, Manit Arya, Mark Emberton, Mathias Winkler, Hashim Uddin Ahmed
Correspondence contact: Deepika.reddy06@imperial.ac.uk

Twitter: @Reddy4Urology, @LondonProstate, @IP_London
Funding sources: Sonacare and Boston (previously Galil and BTG Ltd.)
D. Reddy is funded by Prostate Cancer UK
H.U. Ahmed is funded by Wellcome Trust

INTRODUCTION AND OBJECTIVES

Patients with radio-recurrent localised prostate cancer are traditionally given the option for salvage radical prostatectomy, or undergo hormone therapy. Both options are limited due to complications and associated systemic and functional morbidity.

The study evaluated if Focal Ablative Salvage Therapy (FAST) with cryotherapy and high intensity focused ultrasound (HIFU) may offer a safe alternative, providing oncological control.

METHODS

- All patients were diagnosed using mpMRI followed by transperineal targeted and systematic prostate biopsy.
- If mpMRI was unavailable, all patients underwent template (5mm sampling) biopsy
- All patients were staged with pelvic MRI, cross sectional imaging (CT Chest/Abdomen or PET CT) and bone scan.
- Cryotherapy was used for brachytherapy failure, anterior or seminal vesicle disease
- HIFU: Sonablate device (Sonacare Inc, USA)
- Cryotherapy- IceNet/Visualice system (Boston Scientific)
- Failure-free survival was defined as freedom from systemic therapy, whole-gland treatment, metastases or prostate cancer-specific death (up to 1-2 FAST sessions were permitted)
- Up to hockey-stick ablation was considered focal treatment
- Secondary outcomes included adverse events and overall survival

Focal ablative salvage therapy of the prostate after radiorecurrence, is safe and provides good oncological control at 3 and 6 years

Demographics	
Median follow-up, months (IQR)	41.3 (21.4-58.5)
Median age, years (IQR)	69 (65-73)
Median PSA, ng/ml (IQR)	4.0 (1.7-7.2)
HIFU, % (n)	54.5% (194/356)
Cryotherapy, % (n)	45.5% (162/356)
Quadrant ablation, % (n)	36.0% (128/356)
Hemi ablation, % (n)	18.0% (64/356)
Hockey-stick ablation, % (n)	1.4% (5/356)

Table 1: Patient demographics of patients that underwent focal ablative salvage therapy for radiorecurrent disease, and ablative patterns used.

RESULTS

356 patients underwent FAST between 28/1/2004 and 1/10/2019 for radiorecurrent prostate cancer [Table 1]. FFS (95%CI) at 3 and 6 years were 81% (76-87%) and 75% (68-83%), respectively. Median (IQR) time to failure was 15.5 months (19.7). [Figure 1]. 31 (8.7%) underwent further focal salvage re-treatment

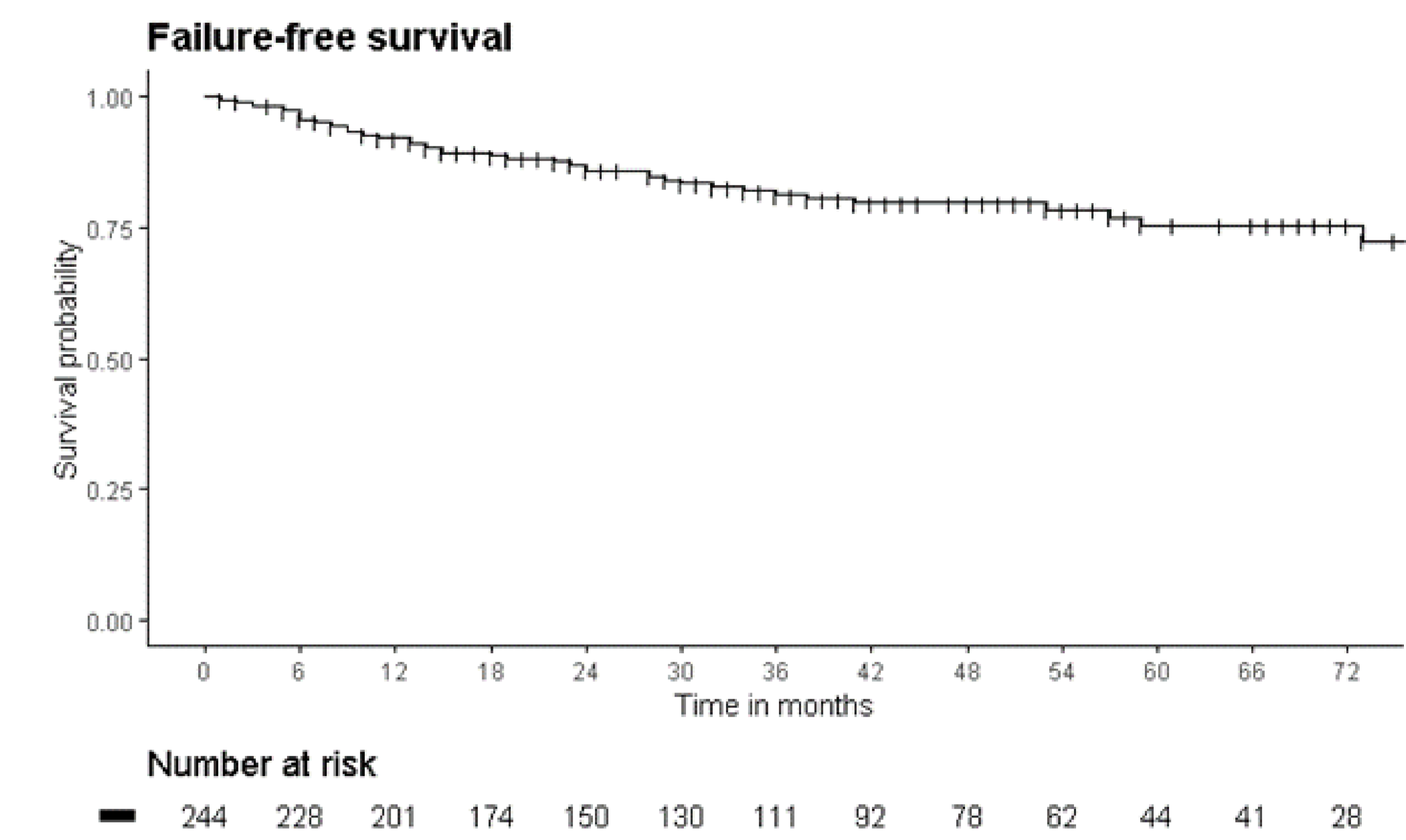


Figure 1: Kaplan-Meier Curve demonstrating failure free survival after focal ablative salvage therapy

Overall survival (95%CI) at 3 and 6 years were 97% (95-100%) and 88% (81-96%) respectively. [Figure 2]. Prostate-specific mortality was 2.8%.

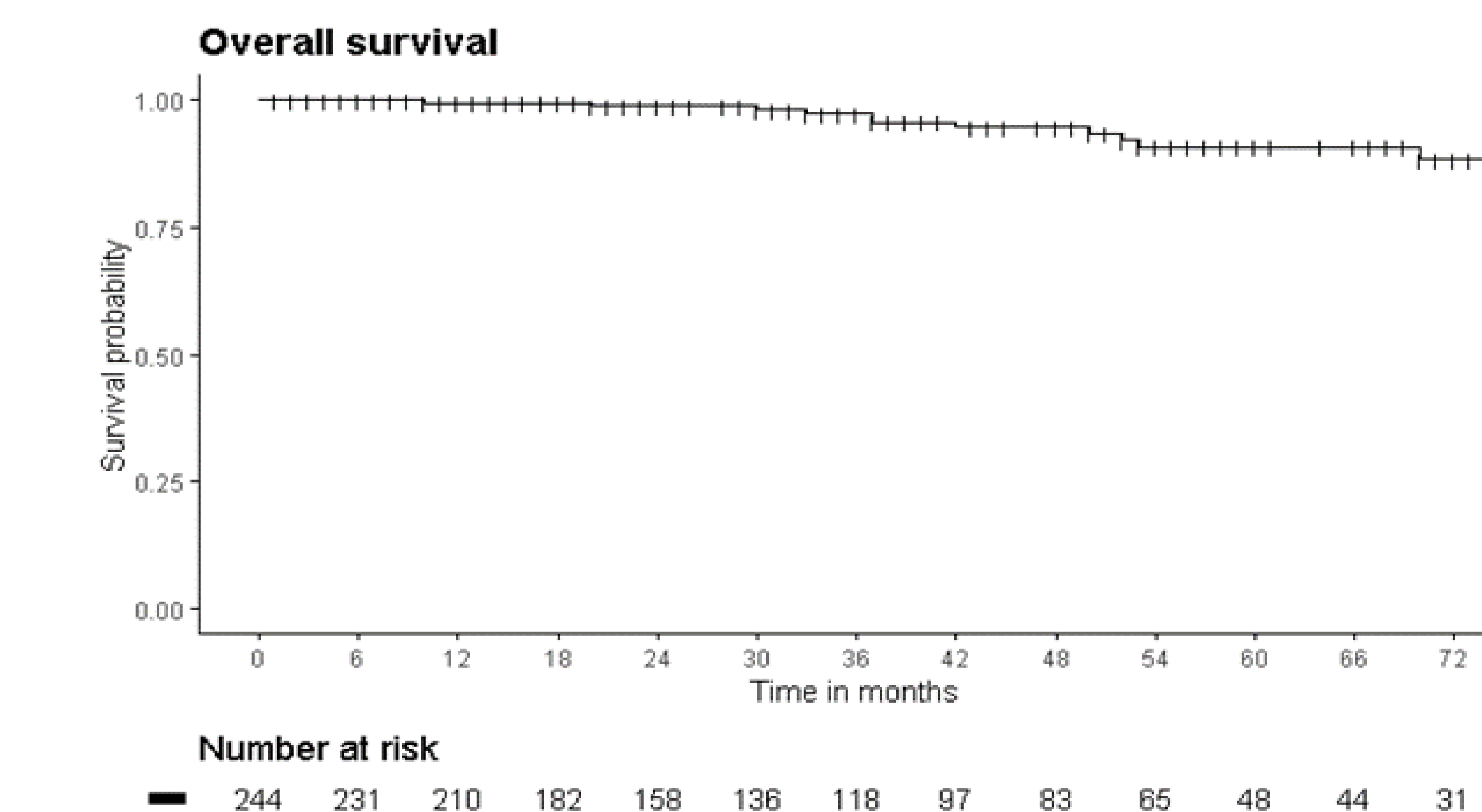


Figure 2: Kaplan-Meier Curve demonstrating overall survival after focal ablative salvage therapy

1 (0.3%) patient was managed for recto-urethral fistula formation, 16 (4.5%) were treated for UTIs.